









## Mastitis and death of a Corriedale ewe associated with *Mycoplasma* spp. infection in Buenos Aires province

Mastitis y muerte en una oveja Corriedale asociada a una infección con *Mycoplasma* spp. en la provincia de Buenos Aires

ARK-CAICYT: <http://id.caicyt.gov.ar/ark:/s26182734/1ubkjvre0>

Germán José Cantón<sup>1</sup> , María Andrea Fiorentino<sup>1</sup> , Eleonora Lidia Morrell<sup>1</sup> , Valeria Scioli<sup>1</sup> ,  
Facundo Urtizbiria<sup>1</sup> , Juan Ignacio Lobo<sup>1</sup> , Erika Sticotti<sup>2</sup> , Pablo Tamiozzo<sup>2</sup> 

1- Instituto Nacional de Tecnología Agropecuaria, EEA Balcarce, Buenos Aires, Argentina.

2- Departamento de Patología Animal, Facultad de Agronomía y Veterinaria, Universidad Nacional de Río Cuarto, Córdoba, Argentina.

**ABSTRACT.** *Mycoplasma* spp. infections are associated with different clinical syndromes in ruminants: mastitis, pneumonia, arthritis, otitis, among others. Nevertheless, case reports of clinical diseases associated with *Mycoplasma*-infections are scarce in small ruminants of Argentina. *Mycoplasma agalactiae* and *Mycoplasma capricolum* are the causal agents of contagious agalactia, an exotic disease in the region. Therefore, strict surveillance of these pathogens is needed. Severe mastitis of a 7-years-old Corriedale ewe in a flock from Buenos Aires province is reported. The affected ewe had delivered twin lambs 15 days before the clinical disease was detected and died. During *post mortem* examination, supramammary lymphadenomegaly was evident. Mammary gland was enlarged and firm, with cyanotic skin and superficial edema; multiple caseous whitish foci were observed in the mammary parenchyma. Similar caseous foci were observed in the caudal-ventral lobes of the right lung. In the histopathological analysis, chronic multifocal necrotizing severe mastitis and fibrinous bronchopneumonia with multifocal necrosis and fibrinous pleurisy were observed. *Mycoplasma* spp. was isolated from the mammary gland. *Mycoplasma* spp. nested-PCR resulted positive in mammary gland and lung. Sequencing analysis confirmed the presence of *Mycoplasma arginini* and *Mycoplasma bovis* in mammary gland and lung, respectively. The pathological findings were similar to the described in cases of contagious agalactia, therefore, *Mycoplasma* speciation was decided in order to discard the presence of this exotic disease.

**KEYWORDS:** mycoplasmosis; *Mycoplasma bovis*; *Mycoplasma arginini*; sheep; mastitis; pneumonia; Argentina.

Artículo recibido: 15 de octubre de 2021

Artículo aceptado: 9 de noviembre de 2021

\***Autor para correspondencia:** Germán José Cantón, Ruta Nacional 226, Km. 73,5, Código Postal 7620, Balcarce, Buenos Aires, Argentina; e-mail: [canton.german@inta.gob.ar](mailto:canton.german@inta.gob.ar)

**Financiamiento:** This study was financially supported in part by FONCyT-ANPCyT-MinCyT, República Argentina (PICT 02148/2018) and Instituto Nacional de Tecnología Agropecuaria (RIST.I111).

**RESUMEN.** Las infecciones con *Mycoplasma* spp. están asociadas con diferentes cuadros clínicos en ruminantes: mastitis, neumonía, artritis, otitis, entre otros. Sin embargo, existen escasos reportes de cuadros clínicos asociados con estas infecciones en pequeños ruminantes de Argentina. *Mycoplasma agalactiae* y *Mycoplasma capricolum* son los agentes causales de la agalactia contagiosa, enfermedad exótica en la región. Entonces, es necesario realizar vigilancia epidemiológica estricta de estos patógenos. Se diagnosticó un cuadro de mastitis severa y muerte en una oveja Corriedale de 7 años de edad, en una majada de la provincia de Buenos Aires. La oveja había parido mellizos 15 días antes que comenzara a manifestar enfermedad clínica y muriera. Durante su necropsia, se observó linfadenomegalia supramaria, glándula mamaria aumentada de tamaño y firme, con piel cianótica y edema superficial. El parénquima mamario presentaba múltiples focos caseosos blanquecinos. Focos caseosos similares se observaron en el lóbulo caudo-ventral del pulmón derecho. En el análisis histopatológico se observó mastitis necrotizante multifocal severa crónica y bronconeumonía fibrinosa con múltiples focos de necrosis pulmonar y pleuritis fibrinosa. Se aisló *Mycoplasma* spp. de la glándula mamaria. Mediante *nested*-PCR, se detectó ADN de *Mycoplasma* spp. en glándula mamaria y pulmón. Mediante secuenciación se confirmó la presencia de *Mycoplasma arginini* y *Mycoplasma bovis* en la glándula mamaria y pulmón, respectivamente. Los hallazgos patológicos fueron similares a los descritos en casos de agalactia contagiosa, por lo que fue necesario determinar que especies de *Mycoplasma* estaban presentes para poder descartar la presencia de esta enfermedad exótica.

**PALABRAS CLAVE:** micoplasmosis; *Mycoplasma bovis*; *Mycoplasma arginini*; ovinos; mastitis; neumonía; Argentina.

## INTRODUCTION

Several *Mycoplasma*-species have been identified in small ruminants causing different clinical signs (DaMassa *et al.*, 1992). *Mycoplasma agalactiae* causes natural disease in both goats and sheep known as “contagious agalactia”. Other species, such as *M. capricolum*, *M. mycoides* ssp. *capri*, *M. mycoides* ssp. *mycoides* (formerly caprine or large-colony biotype), and *M. putrefaciens*, can also provoke mastitis leading to agalactia, keratoconjunctivitis, polyarthrititis, and pneumonia in small ruminants (DaMassa *et al.*, 1992; Gomez-Martin *et al.*, 2013). “Contagious agalactia” is of considerable economic importance because of high morbidity rather than high mortality with impact in the international trade, mainly detected in Europe, Asia, North Africa, and sporadically in the USA and Brazil, classified as notifiable by the World Organization for Animal Health (Ruffin, 2001; OIE, 2018), being exotic in Argentina.

Therefore, surveillance of *Mycoplasma* spp. responsible for “contagious agalactia” is a challenge in countries with a large small ruminant population (Ruffin, 2001; Tardy *et al.*, 2019). This work describes a case of mastitis and death of a Corriedale ewe associated with the presence of *M. bovis* and *M. arginini*.

## CASE DESCRIPTION

### Clinical signs

In September 2019, a 7-year-old Corriedale ewe delivered twin lambs in a flock of 150 sheep, grazing natural grasslands in a commercial farm located in Balcarce (37°47'54"S 58°18'01"W), Buenos Aires province, Argentina. Fifteen days after delivery, the ewe developed severe mastitis and died.

### Necropsy

During *post mortem* examination, mammary gland was enlarged and firm and the skin with cyanotic tint and superficial edema. In mammary parenchyma, multiple to coalescent whitish foci were observed (figure 1). Supramammary lymphonodes were severely enlarged (6 × 3 cm). Multiple to coalescent white caseous foci were also observed in the caudal-ventral lobes of the right lung, affecting around 10% of the respiratory parenchyma (figure 2). No other lesions were observed during the *post mortem* examination.

## Laboratory results

Several tissue samples, including mammary gland, supramammary lymphnodes, lung, heart, kidney, liver, spleen, abomasum, rumen, duodenum and colon, were fixed in 10% neutral buffered formalin, paraffin-embedded, sectioned at 4-5  $\mu\text{m}$  and stained with hematoxylin and eosin (HE) for histologic examination. Microscopically, the mammary gland had multifocal necrotic areas characterized by a band of necrotic inflammatory cells (mainly neutrophils with karyorrhexis and karyolysis) surrounded by a diffuse and severe amount of fibrous tissue admixed with macrophages and lymphocytes (figure 3). In the pulmonary parenchyma, multifocal eosinophilic necrotic areas were observed (figure 4). These necrotic areas were surrounded by a band of neutrophils and macrophages. In addition, the lumen of the alveolus and bronchioles had a severe infiltration composed of neutrophils and macrophages, occasionally mixed by moderate amount of fibrin. The pleura had diffuse and severe amount of fibrin. No other lesions were observed in other tissues.

Mammary gland and lung samples were inoculated onto *Mycoplasma* Base Medium with Selective *Mycoplasma* supplement (MM) (Oxoid Ltd., Wad Road, Basingstoke, UK), Columbia Blood Agar (CBA) (Oxoid Ltd., Wad Road, Basingstoke, UK) with 7% bovine blood and MacConkey agar (MC) (Oxoid Ltd., Wad Road, Basingstoke, UK). All plates were incubated at 37°C, MM under 5% CO<sub>2</sub>, CBA under 10% CO<sub>2</sub> and MC under aerobiosis, and examined at 96, 48 and 24 h, respectively. *Mycoplasma* spp. was isolated from mammary gland (figure 5). CBA and MC cultures were contaminated; therefore, other bacterial pathogens were not detected. DNA was extracted from the mammary gland isolate and the lung specimen using a commercial kit (Puri-Prep S, Inbio Highway, Argentina). A nested-PCR was performed to amplify the intergenic region 16S-23S rRNA of *Mycoplasma* spp. (Nakagawa *et al.*, 1992; Harasawa *et al.*, 1993; Tang *et al.*, 2000) and rendered positive results. In order to identify the *Mycoplasma* species, both PCR products were purified (Puriprep-GP Kit, Inbio Highway), quantified and sequenced (ABI 3130xl; Applied Biosystems) using the inner primers described by Tang *et al.* (2000). The sequences were curated using the BioEdit software (Hall, 1999) and aligned against the database using nucleotide BLAST (<http://www.ncbi.nlm.nih.gov/blast>). The 16S-23S rRNA ITS sequence obtained from the mammary gland isolate (GenBank acces-

sion number OK381582) showed 100% similarity with the same region from eight *Mycoplasma arginini* strains. The sequence obtained from the lung sample (GenBank accession number OK381583) showed 100% similarity with the same region of 78 *Mycoplasma bovis* sequences.

## DISCUSSION AND CONCLUSIONS

Scarce clinical and pathological reports of disease associated with *Mycoplasma* spp. are reported in small ruminants from Argentina. Furthermore, strict surveillance is needed in order to early detect the occurrence of “contagious agalactia”, an exotic disease in Argentina. Therefore, the detection of pathological findings compatible with *Mycoplasma*-mastitis in an ewe of this flock was an alert to immediately confirm the aetiology of this clinical syndrome. Nevertheless, “contagious agalactia” rapidly spread through contact from infected to healthy animals (Gomez-Martin *et al.*, 2013). In this case, it was the only affected ewe.

Fortunately, other *Mycoplasma* species were detected in the affected tissues (mammary gland and lung) of this ewe discarding a case of Contagious agalactia. *M. arginini* can be isolated from various tissues of small ruminants although the organism is mainly considered not mastitogenic, only causing mild alteration in milk consistency and/or appearance (Jones, 1985). *M. arginini* has been also isolated from sheep with keratoconjunctivitis (Leach, 1970) and pneumonia (DaMassa *et al.*, 1992). No clinical mastitis associated with this organism is reported in the literature, therefore, further studies are needed to establish its pathogenic role. Unfortunately, since MC cultures were contaminated, other bacterial pathogens probably co-infecting the mammary gland were not identified.

Besides that, *M. bovis* is usually associated with arthritis, mastitis, pneumonia and otitis in cattle (Pfützner *et al.*, 1996). *M. bovis* can occasionally be isolated from the lungs of goats (DaMassa *et al.*, 1992). In this case, *M. bovis* was detected in the lung and classical pulmonary lesions associated with *M. bovis* infection were observed during the *post mortem* examination and histopathological analysis. No other bacterial pathogen was isolated in these tissues, although co-infections are frequent in these clinical cases. Scarce information about similar clinical and pathological findings are described in the literature in sheep.

This is the first clinical and pathological description of mastitis and pneumonia associated with *Mycoplasma* in sheep from Argentina. These infections should be included in the differential diagnosis of mastitis and pneumonia in sheep.

## BIBLIOGRAPHIC REFERENCES

DaMassa, A.J., Wakenell, P.S., Brooks, D.L. (1992). Mycoplasmas of goats and sheep. *Journal of Veterinary Diagnostic Investigation*, 4: 101-113. <https://doi.org/10.1177/104063879200400126>

Gomez-Martin, A., Amores, J., Paterna, A., De la Fe, C. (2013). Contagious agalactia due to *Mycoplasma* spp. in small dairy ruminants: epidemiology and prospects for diagnosis and control. *Veterinary Journal*, 198: 48-56. <https://doi.org/10.1016/j.tvjl.2013.04.015>

Hall, T.A. (1999). BioEdit: A User-Friendly Biological Sequence Alignment Editor and Analysis Program for Windows 95/98/NT. *Nucleic Acids Symp Series*. 41: 95-98.

Harasawa, R., Mizusawa, H., Nozawa, K., Nakagawa, T., Asada, K., Kato, I. (1993) Detection and tentative identification of dominant mycoplasma species in cell cultures by restriction analysis of the 16S-23S rRNA intergenic spacer regions. *Research in Microbiology*, 144: 489-493. [https://dx.doi.org/10.1016/0923-2508\(93\)90057-9](https://dx.doi.org/10.1016/0923-2508(93)90057-9)

Jones, G.E. (1985). The pathogenicity of some ovine or caprine mycoplasmas in the lactating mammary gland of sheep and goats. *Journal of Comparative Pathology*, 95: 305-318. [https://doi.org/10.1016/0021-9975\(85\)90034-9](https://doi.org/10.1016/0021-9975(85)90034-9)

Leach, R.H. (1970). The occurrence of *Mycoplasma arginini* in several animal hosts. *Veterinary Record*, 87: 319-320.

Nakagawa, T., Uemori, T., Asada, K., Kato, I., Harasawa, R. (1992) *Acholeplasma laidlawii* has tRNA genes in the 16S–23S spacer of the rRNA operon.

*Journal of Bacteriology*, 174: 8163-8165. <https://doi.org/10.1128/jb.174.24.8163-8165.1992>

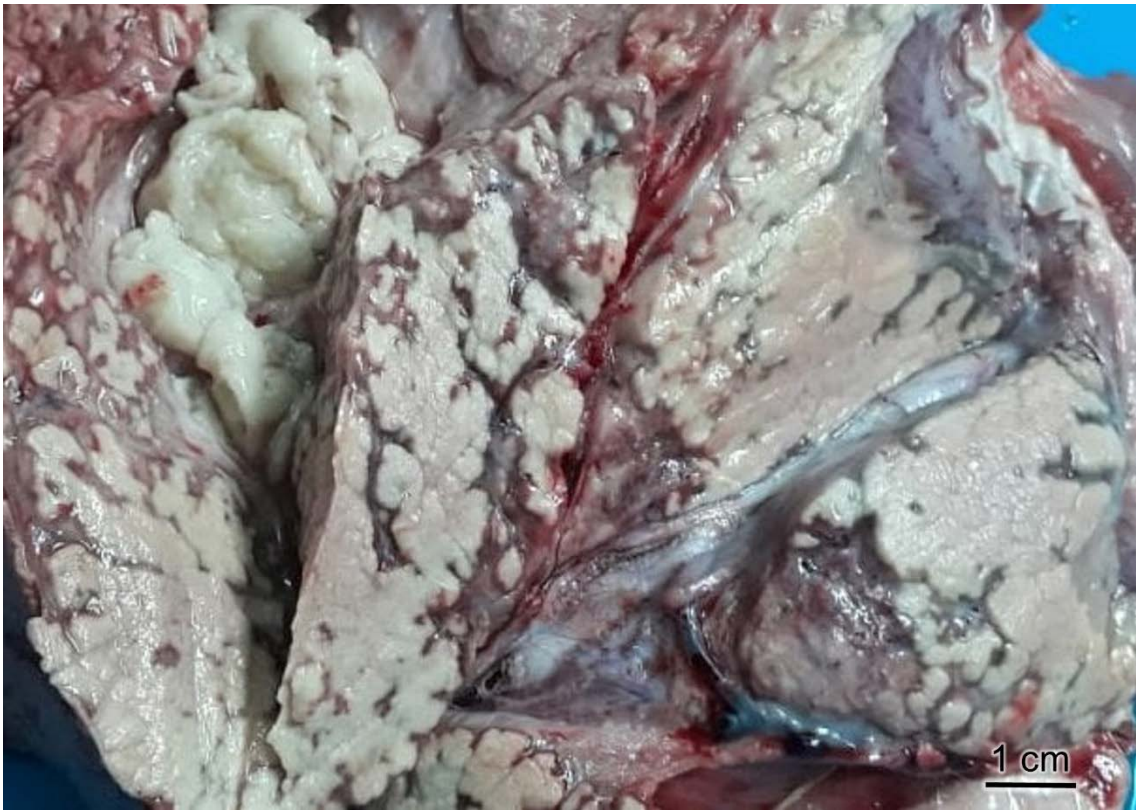Pfützner, H., Sachse, K. (1996) *Mycoplasma bovis* as an agent of mastitis, pneumonia, arthritis and genital disorders in cattle. *Revue scientifique et technique (International Office of Epizootics)*, 15: 1477-1494. <https://doi.org/10.20506/rst.15.4.987>

Ruffin, D.C. (2001). *Mycoplasma* infections in small ruminants. *Veterinary Clinics of North America: Food Animal Practice*, 17(2): 315-332. [https://doi.org/10.1016/s0749-0720\(15\)30031-1](https://doi.org/10.1016/s0749-0720(15)30031-1)

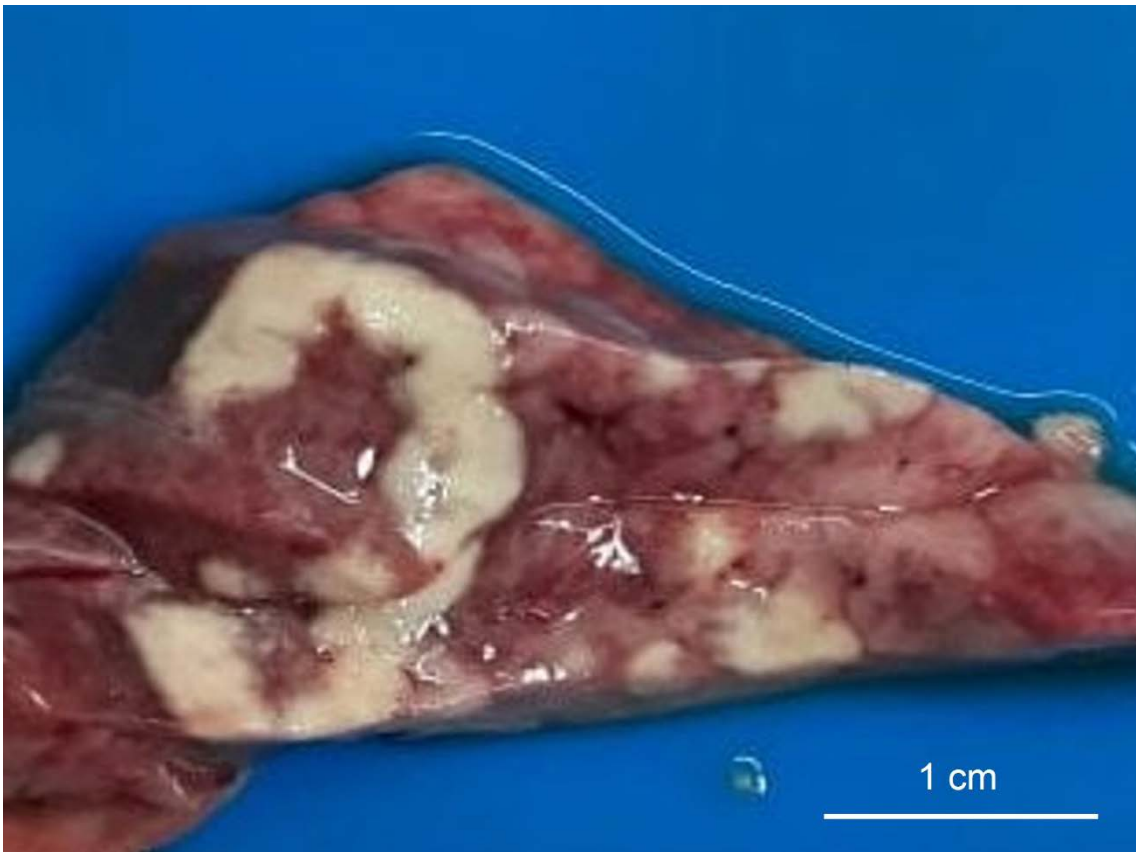World Organisation for Animal Health (OIE). (2018). Chapter 3.7.3. Contagious agalactia. OIE Terrestrial Manual. URL: [https://www.oie.int/fileadmin/Home/fr/Health\\_standards/tahm/3.07.03\\_CONT\\_AGALACT.pdf](https://www.oie.int/fileadmin/Home/fr/Health_standards/tahm/3.07.03_CONT_AGALACT.pdf)

Tang J, Hu M, Lee S, Roblin R. (2000). A polymerase chain reaction based method for detecting *Mycoplasma/Acholeplasma* contaminants in cell culture. *Journal of Microbiological Methods*. 39:121-126.

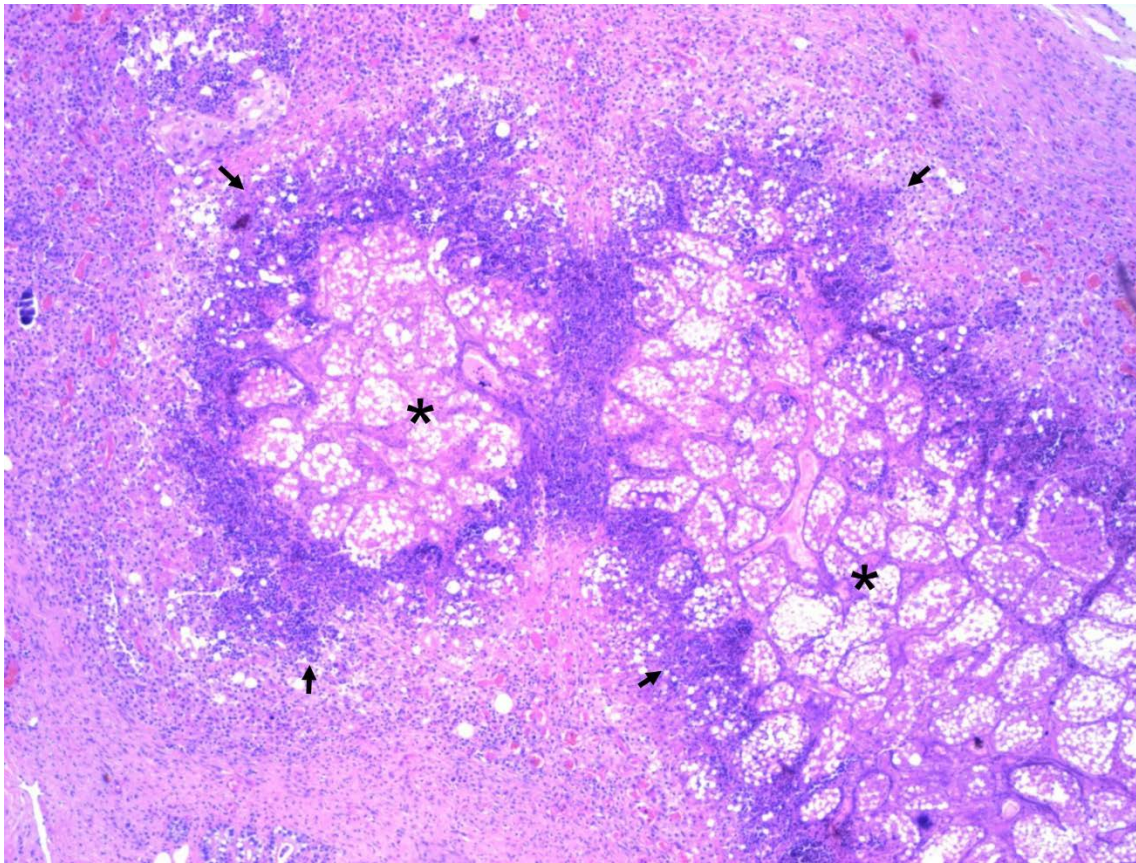
Tardy, F., Treilles, M., Gay, E., Ambroset, C., Tricot, A., Maingourd, C., Vialard, J., Le Grand, D. (2019). Contagious agalactia monitoring in caprine herds through regular bulk tank milk sampling. *Journal of Dairy Science*, 102: 5379-5388. <https://doi.org/10.3168/jds.2018-15889>



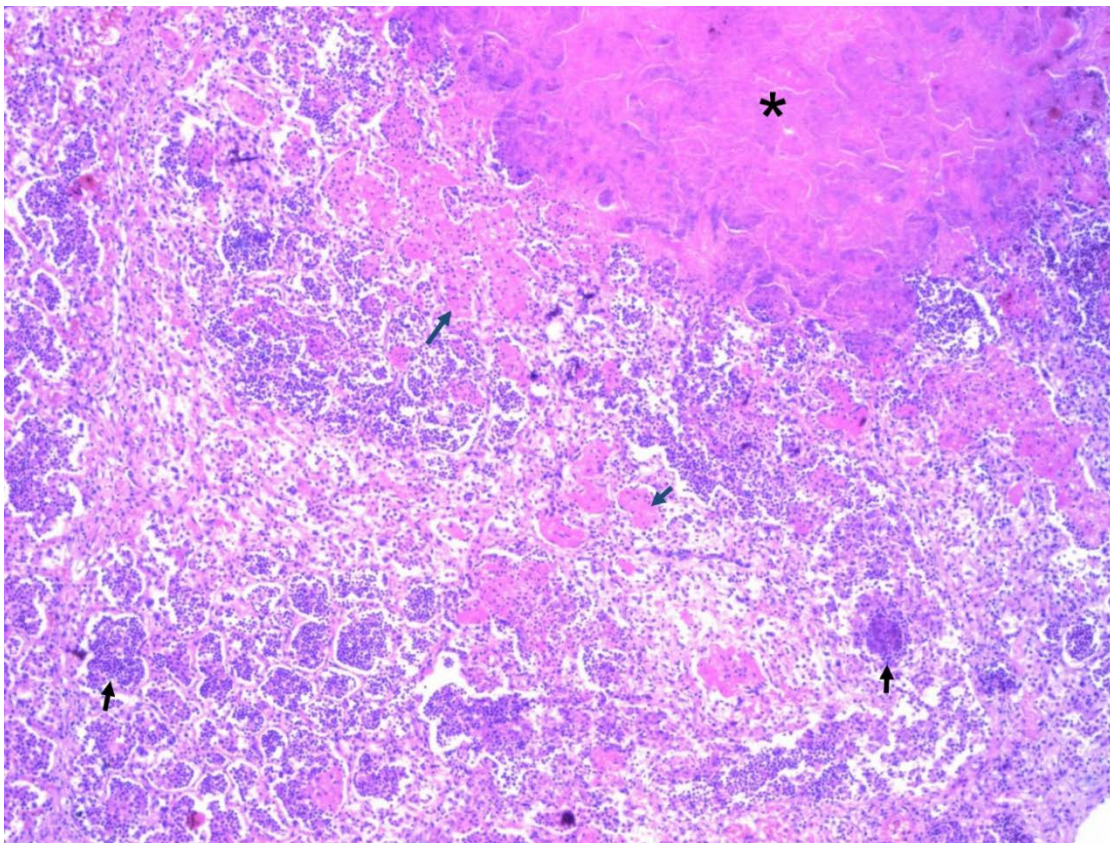
**Figure 1.** Multiple to coalescent whitish foci in the mammary parenchyma.




**Figure 2.** Multiple to coalescent white caseous foci in the caudal-ventral lobes of the right lung.



**Figure 3.** Mammary gland. Unaffected tissue (asterisk) surrounded by a band of necrotic inflammatory cells (arrows). H&E, 100 $\times$ .



**Figure 4.** Lung. Eosinophilic necrotic area (asterisk), inflammatory cells (black arrows) and fibrin (blue arrows) in the lumen of the alveolus. H&E, 100 $\times$ .



**Figure 5.** *Mycoplasma arginini* isolated from the mammary gland (10×).