

First report of a perforated abomasal ulcer in a beef heifer calf in Argentina

Case Report

Volume: 4, Issue: 3
December 2020
Pages: 131-135

Denisa Pérez Gaudio¹, Flavio Pérez², Gustavo Bretschneider³ *

1. Área de Patología, Depto. de Fisiopatología, Centro de Investigación Veterinaria de Tandil (CIVETAN), Universidad Nacional del Centro de la Provincia de Buenos Aires, Tandil, Buenos Aires, Argentina. 2. Eville & Jones. Meat Hygiene Inspection, Norwich, Norfolk, United Kingdom. 3. Instituto Nacional de Tecnología Agropecuaria (INTA) - AER Necochea, Necochea, Buenos Aires, Argentina. Pérez Gaudio, D. ORCID: 0000-0003-2179-7760; Pérez, F. ORCID: 0000-0001-5325-1987; Bretschneider, G. ORCID: 0000-0001-6433-4286

ABSTRACT

Abomasal ulcers are local processes of mucosal autodigestion caused by the disturbance of the balance between protective and aggressive mechanisms in the abomasal mucosa. In order to clarify the etiology, several causes have been discussed and one with a multifactorial origin has been proposed. Signs are mostly non-specific and vary according to different ulcer types. This report describes for the first time in Argentina the clinical case of a perforated abomasal ulcer that induced sudden death in a heifer calf at foot dairy. Necropsy revealed, digestive content in the abdominal cavity and two ulcers in the abomasal mucosa. One ulcer had caused a well-defined 3 cm diameter perforation, which it leading cause has not been determined. Apart from other well known precautions, to minimize the risk of induce perforated abomasal ulcers, stressful management practices should be avoided.

Keywords: calf, abomasal ulcer, perforation

Article History

Received: 13.09.2020
Accepted: 7.12.2020
Available online:
13.12.2020

DOI: <https://doi.org/10.30704/http-www-jivs-net.794447>

To cite this article: Pérez Gaudio, D., Pérez, F., Bretschneider, G. (2020). First report of a perforated abomasal ulcer in a beef heifer calf in Argentina. *Journal of Istanbul Veterinary Sciences*, 4(3), 131-135. **Abbreviated Title:** *J Ist Vet Sci*

Introduction

Abomasal ulcers, local processes of autodigestion of the mucosa (Kureljušić et al., 2013), represent a significant economic problem and an animal welfare concern. They are an important cause of indigestion in dairy cows, feed-lot beef cattle and calves (Braun et al., 1991; Marshall, 2009). Nevertheless, they seem to be more prevalent in grazing dairy cows in the spring and early summer, and in those cows that have concomitant illnesses (Ceelen, 2010). Abomasal ulcers are the result of pathophysiological conditions, where the balance between the protective and destructive processes is disturbed (Kureljušić et al., 2013). In consequence, the resistance of abomasal mucosa is reduced, due to an increase in the secretion of corticosteroids, gastric acid and pepsin in combination with a decreased synthesis of prostaglandins (Braun et al., 1991).

When it comes to clinical findings, both erosions and ulcers may be found in the abomasum (Smith et al., 1983). Abomasal ulcers can be round, oval or polymorph in shape and clearly demarked from the surrounding mucosa. However, they are often burdened with necrotic debris and blood clots. They usually develop as multiple lesions and solitary ulcers are rarely found. Their radius ranges from a few millimeters up to five centimeters (Marshall, 2009). Unlike erosions, which heal by epithelial regeneration without scar formation, ulcers penetrate the entire thickness of the mucosa and may extend through the submucosa, muscularis externa, and serosa. The central crater of the ulcer has a fibrinonecrotic covering and is surrounded by raised, rounded edges. Healing is by wound contraction and granulation tissue formation, thus resulting in a permanent scar. The

*Corresponding Author: Gustavo Bretschneider
E-mail: bretschneider.g@inta.gov.ar

Journal home page: www.jivs.net
<http://dergipark.gov.tr/http-www-jivs-net>



extent of fibrosis present in the submucosa depends on the age of the ulcer (Smith et al., 1983). Ulcers can reduce feed conversion, and they can also progress to perforation with posterior peritonitis and sudden death (Braun et al., 1991). The large curvature of the abomasum is the predilective site for perforations. The most favorable outcome is the development of an abscess on the site of the omentum adhesion triggered by the spill of the content. However, perforations frequently result in bursitis of the omentum and circumscribed or diffuse peritonitis.

The etiology of abomasal ulcers is still unclear; however, after several causes have been suggested, one with a multifactorial origin has been proposed. It is also possible that parallels with the pathophysiological processes occurring in the human ulcer do exist (Hund and Wittek, 2017). Polyvalent stress is often referred to as the principal cause (for example: climate, transport, partum, puerperal period in high yielding dairy cows, calf vaccination and dehorning) (Hund and Wittek, 2017; Kureljušić et al., 2013). Diet also plays an important role. Feeding cattle, whose rumen flora and absorption capacity have not been yet adapted, with large amounts of easily fermentable carbohydrates, can cause ruminal acidosis. The resulting lactate and histamine in the rumen subsequently lead to stasis of the ingested food and hyper-secretion of hydrochloric acid and pepsin in the abomasum. This favors damage to the protective mucus layer and the development of abomasal ulcers. The reflux of bile acids that acts as detergents in the abomasum also affects the mucus layer (Braun et al., 1991). Thus, acidification of the abomasum is considered as major cause of ulcer development, as damage to the protective mucus layer allows hydrogen ions to diffuse from the lumen into the mucous membrane and the proteolytic enzyme pepsin to penetrate the deeper layers of the wall of the abomasum. These can ultimately lead to ulceration from self-digestion (Hund and Wittek, 2017). Fewer meals with large amounts of milk, along with peristalsis in the pars pylorica of the abomasum, cause ischemia with damage to hypoxic tissues that promotes the development of abomasal ulcers due to microcirculation disorders. In contrast, frequent feeding of dairy calves leads to an increase in the mean abomasum pH and thus it could be a protective factor in the prophylaxis of abomasal ulcers (Ahmed et al., 2002). Copper deficiency has been associated with abomasal ulcers since copper plays an important role in the functionality of the immune system and is responsible for the integrity of the blood vessels in the abomasum (Mills et al., 1990). Microthrombi in damaged vessels cannot be excluded as a cause of

ulcers. Abrasive agents, such as hairballs (trichobezoars) (Jelinski et al., 1996), sand, or stones can have a predisposing effect due to the trauma they may cause on the abomasal wall. Straw, as the sole forage for milk-fattening calves, is also suspected of being detrimental to calf health and has been linked to an increased incidence of abomasal lesions (Bähler et al., 2010). Infections associated with some fungi and bacteria have also been associated with abomasal ulcers. Among them, *Clostridium perfringens* type A, *Helicobacter pylori*, *Campylobacter* spp. (Hund and Wittek, 2017) and *Candidatus helicobacter bovis* have been pointed out. Side effects of anti-inflammatory drugs, mainly those which are not approved for use in cattle, are also related to the occurrence of abomasal ulcers. Prostaglandin E has an important protective function for the stomach. Steroidal and non-steroidal anti-inflammatory drugs (NSAIDs) inhibit prostaglandin synthesis by blocking the enzyme cyclooxygenase (COX), leading to a reduction in mucus production and changes in microcirculation, which favors the development of ulcers (Hund and Wittek, 2017). Furthermore, abdominal ulcers are generally associated with comorbidities. In dairy cows, these are primarily abomasal displacements (usually to the left) (Braun et al., 1991; Brown et al., 2007; Marshall, 2009), but also metritis, ketosis, mastitis, milk fever, lipomobilization syndrome, liver diseases and pneumonia. The oncogenic presentation of bovine leukosis (lymphosarcoma) can cause ulceration due to its predilection for the abomasum (Ceelen, 2010). Abomasal ulcers have also been described in cows with mycotic ulcerative abomasitis with poor immune response due to infection with vasoactive fungi.

The peptic ulcers of the abomasum should be also distinguished from secondary ulcers which accompany malignant catharral fever, mucosal disease, rinderpest, actinomycosis and tuberculosis (Brown et al., 2007; Kureljušić et al., 2013). Abomasal ulcers have been classified into four or five types by different authors. Occasionally more than one ulcer type occurs at the same time (Braun et al., 2016). Type 1 abomasal ulcer is an erosion or a non-open ulcer. In this case, the abomasum wall is intact but the mucosal barrier is destroyed. This leads to minimal bleeding into the lumen of the abomasum and local wall thickening and serositis (Hund and Wittek, 2017). Type 2 ulcer is associated with severe intraluminal haemorrhages due to the erosion of a large blood vessel. In types 3 and 4 ulcers, abomasum is perforated. Type 3 ulcers are characterized by localized peritonitis with the adherence of the abomasum to surrounding structures such as the omentum or peritoneum. In type 4 ulcers, the

ingestion spills into the abdominal cavity, leading to generalized peritonitis. In addition to those mentioned above, a perforated ulcer accompanied by peritonitis within the omental bursa was once previously considered a subtype of type 3 ulcers, but it has recently been reclassified as "type 5 abomasal ulcer" (Braun et al., 2016).

Ante-mortem diagnosis of abdominal ulcers is often difficult due to the frequent lack of clinical signs (Hund and Wittek, 2017). Even deep ulcers can remain unapparent until their perforation and only the resulting peritonitis leads to the corresponding clinical signs. Therefore, dairy calves with an abomasal ulcer are often completely normal until they reject milk intake, as a first sign. On the other hand, bleeding abomasal ulcers, cause a clearer clinical picture, with the presence of blood in the manure (melena), which is darker than normal, often black and tarry. The typical appearance of the manure is caused by blood digestion, which points out that the bleeding, which abomasal ulcers are the most common cause of, is located in the upper gastrointestinal tract (Ceelen, 2010). In addition, this situation is generally associated with ileus signs (for example, increased circumference of the right ventral abdomen). Generally, affected cows will only eat long stem roughage, such as hay and they are reluctant to eat silages, grains, and total mixed rations. Other cattle herd signs mostly known to be a prelude to clinical abomasal ulcers or that occur simultaneously, include: low herd milk fat percentage, variable and often low herd dry matter intakes, a higher incidence of lameness in the herd (sole ulcers, hemorrhagic soles and white line abscesses), a wide variety of manure consistencies within the herd, from very loose (diarrhea) to firm, with each individual showing loose or firm feces one day, and the opposite a day later (Ceelen, 2010). In calves, perforated abomasal ulcers generally cause a noticeable posture, with pulled up abdomen (filled on both sides with increased abdominal wall tension), lowered head, drooping ears, wet muzzle and throat accompanied by an "empty look". Interestingly, as was previously mentioned, abomasum displacements are common in calves and they are often associated with perforated abomasal ulcers. Yet, which of these two problems stands as the cause and the other one as the result, remains unclear (Hund and Wittek, 2017). Due to non-specific signs, diagnosis in live animals is not easy. Imaging procedures such as endoscopy, which are used in monogastric animals, are not suitable for ruminants by the reason of their specific anatomy. Likewise, there are no procedures or laboratory parameters

that allow a clear diagnosis. Due to blood loss, anemia can also be found. Detection of occult blood in manure can be helpful and indicative of bleeding stomach ulcers. In certain cases, when a perforated abomasal ulcer is suspected, ultrasound examination may be helpful in reaching a diagnosis. But it is important to highlight that the ulcers themselves cannot be visualized with ultrasound. However, ultrasound examination is adequate and useful to visualize the changes associated with perforated ulcers. Type 3 ulcers can appear sonographically as traumatic fibrinous reticuloperitonitis (Katchuik, 1992). In the case of peritonitis, abdominocentesis can be useful as a diagnostic tool. Exploratory laparotomy is another diagnostic procedure to clarify non-specific abdominal signs.

Treatment of abomasal ulcers can be symptomatic, surgical, or medicinal. If anemia is present, a blood transfusion is considered for symptomatic treatment. Ruminal fluid transfer may also be helpful to stabilize microflora in the digestive tract. There are only a few options for the drug treatment of abomasal ulcers. In calves with non-perforated ulcers, surgical treatment with resection of the ulcer is described. However, as mentioned above, most calves do not show clear clinical signs until the ulcer is perforated and has caused severe peritonitis. In this case, due to the almost unfavorable prognosis, surgical intervention comes too late (Hund and Wittek, 2017).

When it comes to prophylaxis, since the exact relationship between the etiology and pathogenesis of abomasal ulcers has not been identified so far, it is very difficult to formulate prophylactic measures.

Case report

In an Aberdeen Angus cow-calf operation located at Pieres (38°18'S; 58°40'W), in Lobería county, province of Buenos Aires, Argentina, a 2 months old heifer calf (body weight: approx. 100 kg) was found reclining on its right flank and unable to rise. This calf at foot dairy, had no previous signs and died a few hours after it was found. The cow-calf herd was fed on a pasture composed of Mediterranean alfalfa (*Medicago sativa subesp. sativa*), prairie grass (*Bromus catharticus*), red clover (*Trifolium pratense*) and Mediterranean fescue (*Festuca arundinacea*). Spring calving cow herd had a very good body condition and, particularly, the mother of the dead calf was a multiparous cow and had a healthy udder producing an adequate milk supply.

At the necropsy, it was observed digestive content in the abdominal cavity and a well-defined perforation in the abomasum (Figure 1). However, there was no

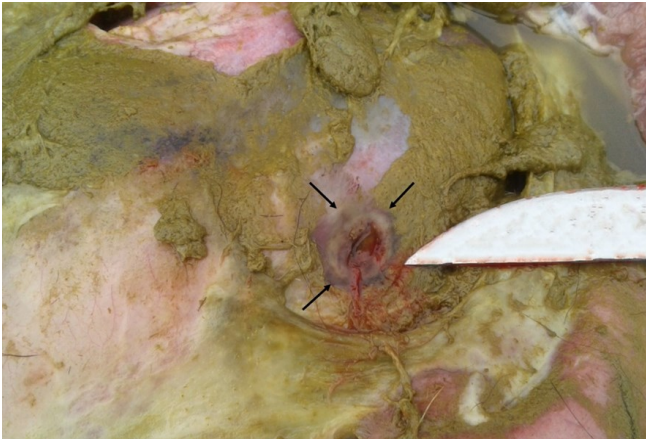


Figure 1. Digestive content in the abdominal cavity and the well-defined perforation found in the abomasum. Arrows show the perforation site.

evidence of peritonitis or adhesions. At the opening, the mucosa of the abomasum presented two ulcers, one of 3 cm in diameter with an irregular perforation in the center (Figure 2) and the other, smaller (2 cm diameter) without perforation. Abrasive objects were not found into the digestive tract. Moreover, the rest of the organs did not exhibit evident alterations.

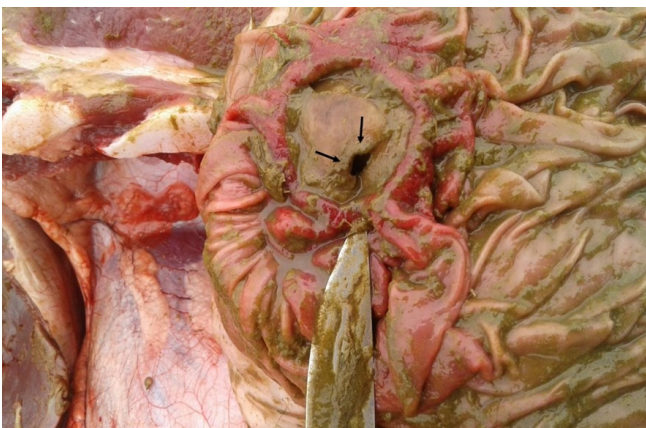


Figure 2. Perforated abomasal ulcer in the calf presented in this study. Arrows show the perforation site.

Discussion and conclusion

Considering that most of abomasal ulcers may be subclinical, in absence of dark, tarry manure, it is difficult to conclusively arrive at abomasal ulcers diagnosis. In our case, perforated abomasal ulcer was diagnosed by necropsy examination. The radius of the perforation may play a decisive role for the developing ulcer type, thus, radius of 1 to 3 mm on the perforation site results in type 3 ulcers while perforations from 1.25 to 3 cm result in type 4 ulcerations (Kureljušić et al., 2013). The perforated ulcer presented in this case was of 3 cm diameter (i.e; 1.5 cm radius), which could be classified as type 4 ulcer. In Canadian cow-calf operations, over a decade, 209 calf deaths were reported to be caused by

abomasal ulcers. Of the total, 93.3% of the lesions corresponded to perforating ulcers while 6.7% were in concordance with hemorrhagic ones. The episodes, mostly subclinical, were mainly recorded in calves with ≤ 2 months of age (86% of cases). There was no predisposition associated with sex or breed. It is important to note that none of the previously listed ulceration causes have been scientifically associated as a causative agent of abomasum ulcers of these cows (Jelinski et al., 1996). On the other hand, in particular, hairballs were found in 35 of 46 cases of abomasal ulcers (Wittek et al., 2016). However, the role they played in the development of ulcers has been rejected, considering that the friction exerted by a hairball on the abomasal mucosa would be unable to erode it. In the clinical case reported here, no hairballs were found in the abomasum. In dairy calves in Switzerland, abomasal ulcers are known to be responsible for 25% of all deaths, with a prevalence of 0.2-5.7% (Hund and Wittek, 2017). The fact that the highest number of cases was reported in calves up to 2 months of age, reveals an association between the formation of ulcers and the development of pre-ruminant stomachs. The transition process between pre-ruminant to ruminant occurs between the third and eighth week of life. In other words, both the pre-ruminant period (<3 weeks old) and the period of transition to ruminant (3 to 8 weeks old) represent the moments of lifetime in which calves are most susceptible to death from an abomasal perforated ulcer. However, the cause associated with the physiological transition to ruminant which triggers the development of abomasal ulcers, is still unknown (Jelinski et al., 1996). Taking this into consideration the death of the calf reported in this study seems to be supported by data and within risk range of age. *Clostridium perfringens* and *Campylobacter jejuni* have been described in relation to abomasal ulcers in calves. Nevertheless, a recent study in dairy calves, found no differences between healthy calves and ulcerated calves with regard to the presence or the absence of *Clostridium perfringens*. *Candidatus helicobacter bovis* has been proposed as a new potentially ulcerogenic agent, although its involvement in gastric disease in cattle is presently unknown. Other bacteria, such as *Helicobacter spp.*, which is clearly associated with gastric ulcers in humans, has not been detected in dairy calves. Therefore, the role of these bacteria in the pathogenesis of abomasal ulcers can be classified as low to non-existent (Hund and Wittek, 2017).

Differential diagnoses for abomasal ulcers differ between ulcer types and according to the animal's

age. Overall, for perforated abomasal ulcers, the differential diagnosis includes, omphalitis, uterine rupture, traumatic reticuloperitonitis rumen bloat, endoparasites, and peritonitis, among others (Hund and Wittek, 2017).

For prophylactic purposes, in general, cattle husbandry practices that induce calf stress should be minimized, since particularly, well-developed calves often die by perforated abomasal ulcers within days of these practices (Braun et al., 1991).

It is also important to point out that the death, reported herein, corresponds to medical foresights when discussing about a calf born and raised in an extensive pasture-based cow-calf operation system that cares cattle well-being. Despite the relationships in the development of abomasal ulcers remain without being fully understood, their multifactorial genesis is unquestionably. This fact has made it impossible to reach the leading cause of the perforated abomasal ulcer reported herein. Nevertheless, as it was previously described, the most plausible cause may be associated to the pre-ruminant to ruminant transition.

Conflict of interest

The authors have no conflicts of interest to declare.

References

- Ahmed, A. F., Constable, P. D. & Misk, N. A. (2002). Effect of feeding frequency and route of administration on abomasal luminal pH in dairy calves fed milk replacer. *Journal of Dairy Science*, 85 (6), 1502-1508.
- Bähler, C., Regula, G., Stoffel, M. H., Steiner, A. & von Rotz, A. (2010). Effects of the two production programs 'Naturafarm' and 'conventional' on the prevalence of non-perforating abomasal lesions in Swiss veal calves at slaughter. *Research in Veterinary Science*, 88(2), 352-360.
- Braun, U. (2016). Ascites in cattle: Ultrasonographic findings and diagnosis. *Veterinary Clinics: Food Animal Practice*, 32(1), 55-83.
- Braun, U., Bretscher, R. & Gerber, D. (1991). Bleeding abomasal ulcers in dairy cows. *The Veterinary Record*, 129(13), 279-284.
- Brown, C. C., Baker, D. C., Barker, I. K. (2007). *The alimentary system*. In Jubb K. F., Kennedy P. C., & Palmer N. (Ed). *Pathology of Domestic Animals*. 5th ed. (pp 1-297). San Diego, US: Academic Press.
- Ceelen, H. (2010, March 1). Prevent abomasal ulcers. *Vet's Corner. Ontario Dairy Farmer*, 74-75. Retrieved from <http://oabp.ca/wp-content/uploads/2014/02/Abomasal-Ulcers.pdf>.
- Hund, A. & Wittek, T. (2017). Labmagengeschwüre beim Rind. *Tierärztliche Praxis Ausgabe G: Großtiere/Nutztiere*, 45(02), 121-128.
- Jelinski, M. D., Ribble, C. S., Campbell, J. R. & Janzen, E.D. (1996). Descriptive epidemiology of fatal abomasal ulcers in Canadian beef calves. *Preventive Veterinary Medicine*, 26(1), 9-15.
- Katchuik, R. (1992). Abomasal disease in young beef calves: surgical findings and management factors. *The Canadian Veterinary Journal*, 33(7), 459.
- Kureljušić, B., Ivetić, V., Savić, B., Jezdimirović, N., Cvetojević, Đ., Kureljušić, J. et al. (2013). Pathomorphological characteristics of abomasal ulcers in high-yielding dairy cows. *Acta veterinaria*, 63(2-3), 237-246.
- Marshall, T. S. (2009). Abomasal ulceration and tympany of calves. *Veterinary Clinics of North America: Food Animal Practice*, 25(1), 209-220.
- Mills, K. W., Johnson, J. L., Jensen, R. L., Woodard, L. F. & Doster, A. R. (1990). Laboratory findings associated with abomasal ulcers/tympany in range calves. *Journal of Veterinary Diagnostic Investigation*, 2(3), 208-212.
- Smith, D. F., Munson, L. & Erb, H. N. (1983). Abomasal ulcer disease in adult dairy cattle. *The Cornell Veterinarian*, 73(3), 213-224.
- Wittek, T., Ernstberger, M., Muckenhuber, M. & Flöck, M. (2016). Effects of wheat protein in milk replacers on abomasal emptying rate in calves. *Journal of Animal Physiology and Animal Nutrition*, 100(2), 264-270.